

Assessment of Acaricidal Efficacy of Ivermectin Against Ectoparasitic Skin Lesions in Goats

Aurangazeb Kabir, Md. Khairul Islam, Most. Sabina Yasmin, Md. Emtiaj Alam and Mohammad Mahbubur Rahman

ABSTRACT

We have conducted a research experiment to investigate the efficacy of commercial Ivermectin preparations (Ivertin®, Invet®, and A-Mectin®) against skin lesions in goats. The generic Ivermectin is, in fact, a naturally-derived dihydro derivative of avermectin originating exclusively from a single microorganism isolated from Japanese soil, displaying an extensive range of antiparasitic efficacy against internal and external parasites of human and domestic animals. The ectoparasites such as ticks, lice, and mites cause heavy economic losses to the livestock industry due to their blood-sucking habit, which adversely affects economic production. Ectoparasites have been recognized as the notorious threat due to severe irritation, formation of crust, wrinkled, thickened, and or loss of hair, allergy, and toxicosis and eventually brought about financial havoc in goat farming. Presently, this is the best-known drug available for combating ectoparasitic diseases in livestock. After being bound, the drug disrupts parasitic neuromuscular transmission, causing hyperpolarization of the neuronal membrane, inducing paralysis of somatic muscles, particularly the pharyngeal pump, killing the parasites. To investigate the comparative efficacy of commercially available different ivermectin preparations in the local market against skin lesions in goats, the research work was conducted on 12 goats of both sexes having skin lesions from July to August 2017. Subcutaneous injection of Ivertin® of Chemist Laboratories Ltd, Invet® of Popular Pharmaceuticals Ltd, and A-Mectin® of The Acme Pharmaceuticals Ltd, Bangladesh @ 1 ml per 50 Kg bwt where each ml contains 10mg of generic Ivermectin on the first day followed by the second dose at 7th day and the third dose at 14th day of experimentation. Our results revealed within 28 days of treatment with these preparations of Ivermectin, both smaller and larger skin lesions in goats of all experimental groups were almost cured at a rate of 99%. No adverse effect was observed following ivermectin therapy. The animals were seen with increased vigor, better growth, and improved coat color. Although the precise mode of action and interactions of Ivermectin is yet to be revealed fully, the drug certainly had a tremendously positive effect in alleviating ectoparasitic diseases from goats.

Keywords: Effectiveness, goat, Ivermectin, skin lesions.

Published Online: March 1, 2022

ISSN: 2736-6596

DOI: 10.24018/ejvetmed.2022.2.2.22

A. Kabir*

Department of Veterinary and Animal Sciences, University of Rajshahi, Rajshahi-6205, Bangladesh.

(e-mail: aurangak@yahoo.com)

M. K. Islam

Department of Veterinary and Animal Sciences, University of Rajshahi, Rajshahi-6205, Bangladesh.

(e-mail: mdkhairulislam.ru@gmail.com)

M. S. Yasmin

Department of Veterinary and Animal Sciences, University of Rajshahi, Rajshahi-6205, Bangladesh.

(e-mail: sabinayasmin12208306@gmail.com)

M. E. Alam

Department of Veterinary and Animal Sciences, University of Rajshahi, Rajshahi-6205, Bangladesh.

(e-mail: emtiajalam8303@gmail.com)

M. M. Rahman*

Department of Veterinary and Animal Sciences, University of Rajshahi, Rajshahi-6205, Bangladesh.

(e-mail: mmrahman@ru.ac.bd)

*Corresponding Author

I. INTRODUCTION

Bangladesh is one of the densely populated agricultural countries globally [1]. Livestock is one of the four significant components of agriculture, others being crops, fisheries, and forestry, that plays a vital role in the national economy. At present, livestock contributes 6.5% to G.D.P. based on value-added through the production of milk, meat, hide, skin and eggs. The country earns about 13% of foreign exchange by exporting hide and skin, and the leather sector has been an essential contributor to the country's G.D.P., its share standing at 28.6% in 2011 [2].

Goats are a significant group of livestock that are mainly reared for meat purposes in Bangladesh. Some breeds are raised for wool production. Goats available in Bangladesh are

of the indigenous type with small body sizes and produce hairy and coarse wool of varied colors. The goat is primarily raised for meat in our country, and no attention is given to wool production. Goat is much more tolerant to environmental adversaries than other livestock counterparts. Taking the economic matter into key consideration, most families in rural areas of Bangladesh rear goats. The goat as a whole has a high market value. Primarily Black Bengal goat produces high-quality meat and skin. Goat's milk is very palatable and easily digestible. Their dung is used as agro fertilizer, hides, skin, and wool are considered sources of earning foreign currency. To uplift the national economy and meet dietary demand, greater emphasis should be put on a goat and other livestock production.

Various skin diseases are prevalent in livestock, which may cause a severe loss in product performance. In young animals, skin diseases were the second major group (14.92%) of maladies. This finding supports the report of Debnath et al. who also recorded skin diseases (20.63%) as the second major group of diseases observed [3]. The healthy and normal skin acts primarily as an organ of protection and thus maintains homeostasis. Various skin diseases are prevalent in livestock, which may cause a severe loss in production performance. Dermatitis (9.64%) was recorded as a significant skin disease, followed by ectoparasitism (2.54%) and skin wound (2.13%) with a limited incidence of burn (0.36%) and myiasis (0.24%) cases [4]. In livestock, 8.47% dermatitis incidence was reported by two eminent scientists from Bangladesh [5]. Among the various skin diseases, external wounds are one of the crucial problems of animals.

Ivermectin is a well-known antiparasitic drug with high lipophilicity that dissolves in most organic solvents but is practically insoluble in water (0.0004% m/v), being extensively used in humans and veterinary medicine around the world. It is a mixture of two chemically modified avermectins that contain at least 80% of 22, 23-dihydroavermectin-B1a, and >20% 22, 23-dihydroavermectin-B1b. It is a safe drug with a high therapeutic safety index, and no reports of its toxicity have ever been recorded around the globe. The drug was first marketed in 1981 by Merck Sharp and Dohme as an antiparasitic agent and it remains the leading worldwide antiparasitic agent for livestock [6]. It works by stimulating the release of GABA from the nerve ending and enhancing the binding of GABA to special receptors at nerve junctions. It has exceptional potency against endo- and ectoparasites, including sensitive mites, ticks, biting flies, and parasitic dipterans larvae at extremely low ($\mu\text{g/kg}$) doses [7], [8].

The discovery and synthesis of this wonder drug traced back to 1970 when renowned Japanese Microbiologist Dr. Satoshi Omura collected a soil sample from a forest close to a golf course in Kawana, on the southeast coast of Honshu, Japan [9]. Omura isolated and cultured a Gram-positive bacterium, a then-unknown species of *Streptomyces*. After initial laboratory evaluation at Tokyo's Kitasato Institute, this mysterious species of *Streptomyces* and 50 other promising bioactive strains of *Streptomyces* that seemed unusual in appearance or culture characteristics were then sent to Dr. William Campbell at Merck laboratory, the U.S.A. for further in vivo testing. Cultures showed potent activity against *Nematospiroides dubious* (now *Heligomosoides polygyrus*) infection in mice, and the active components were purified, revealing a family of macrocyclic lactones. These naturally occurring compounds were named the avermectins and the bacterium, *Streptomyces avermitilis* to reflect the vermin (worm)-free 'verminous' conditions they produced [10], [11]. The safer and more effective derivative, Ivermectin, was subsequently commercialized, entering the veterinary, agricultural, and aquaculture markets in 1981 by U.S.A. based world's largest pharmaceutical company Merck Sharp and Dohme (M.S.D.), as an antiparasitic agent and it remains the leading worldwide antiparasitic agent for livestock [6].

Ivermectin is a highly lipophilic substance that dissolves in most organic solvents like methylene chloride, ethanol, etc., but is practically insoluble in water (0.0004% m/v). It has a

more considerable margin of safety with exceptional potency against endo- and ectoparasites at shallow doses. The drug's potential in human health was confirmed a few years later, and it was registered in 1987 and immediately supplied for treating disease free of cost branded as Mectizan®. Despite decades of searching worldwide, the Japanese microorganism remains the only source of avermectin ever found [12]. Dr. William C. Campbell of Merck Laboratories and Japanese Microbiologist Dr. Satoshi Ōmura were awarded 2015's Nobel prize in medicine or physiology for discovering avermectin, the derivatives of which drastically lowered the incidence of river blindness and lymphatic filariasis, as well as showing efficacy against an expanding number of other ecto and endoparasitic diseases [9]. Although Ivermectin is a safe drug with high therapeutic activity against endo and ectoparasites, various commercial preparations are rampant. Still, their effectiveness in the field sometimes remains disputed. Thus different commercial ivermectin preparations plus associated factors of the drug potency need to be reviewed. Keeping that into consideration, it is, therefore, imperative to assess the efficacy of commercially available different ivermectin formulations in the local market against skin lesions in goats.

II. METHODOLOGY

A. Location of the Study Area

We attempted to determine the comparative efficacy of commercially available different ivermectin formulations in the local market against skin lesions in goats. The experiment was conducted from July to August 2017. The experiment was conducted at Damurhuda Upazila under the district of Chuadanga in co-operation with the Department of Veterinary and Animal Sciences, University of Rajshahi, Rajshahi.

B. Collection of Animals

We have selected twenty-four (24) goats of both sexes of 1-2 years of age having skin lesions for the experiment purposes. We collected all the goats from Damurhuda Upazila under the district of Chuadanga. The period of the survey was from July to August 2017. We adapted the following procedures for experimenting.

C. Materials Required (Instrument and Appliances)

- i) Ivermectin injection
- ii) Syringe with needle
- iii) Gloves
- iv) Measuring scale
- v) Measuring tape
- vi) pen
- vii) Notebook
- viii) Cotton
- ix) Paper
- x) Camera
- xi) Tissue paper etc.

D. Collection of Drugs

Ivermectin injection (S/C formulation) of three leading pharmaceutical companies viz: Ivertin® of Chemist Laboratories Ltd, A-Mectin® of ACME Laboratories Ltd, and

Invet® of Popular Pharmaceutical Limited was purchased from the local market, Chuadanga, Bangladesh.

E. Selection of Animal

We selected twenty-four (24) goats of both sexes having skin lesions for experimenting. The age of goats ranged between 1 to 2 years, and the body weights of goats were 12-25 kg.

F. Experimental Design

We divided these goats (24) into four equal groups. We treated the goats of three groups with Ivermectin. The rest was kept as a control group as per the following schedule.

TABLE I: IVERMECTIN DRUG REGIMEN FOR GOATS

Group of Animal	Drug with dose and route
Group A	Without treatment (Control)
Group B	Ivertin® @ 200 µg /kg body weight, SC
Group C	A-Mectin® @ 200 µg /kg body weight, SC
Group D	Invet® @ 200 µg /kg body weight, SC

Group A: Goats of Group-A were kept as the infected control group.

Group B: Ivermectin (Ivertin®, S/C formulation) was applied subcutaneously on the first day around the lesions using a sterile disposable syringe

@ 200 µg per kg body weight in goats was repeated on 7th & 14th day of the first injection.

Group C: Ivermectin (A-Mectin®, S/C formulation) was applied subcutaneously on the first day around the lesions using a sterile disposable syringe @ 200 µg per kg body weight in goats was repeated on 7th & 14th day of the first injection.

Group D: Ivermectin (Invet®, S/C formulation) was applied subcutaneously on the first day around the lesions using a sterile disposable syringe @ 200 µg per kg body weight in goats and was repeated on 7th & 14th day of the first injection.

The fate of the lesions was inspected in all groups at every seven alternative days for several weeks from the first application of the drugs. Efficacy of Ivermectin was assessed by clinical healing of the lesions was used as criteria for investigation and evaluation of the drugs. We measured the skin lesions at four days intervals during the experimental period.

G. Statistical Analysis

We analyzed the results of the treated and untreated groups by using the student's test (t-test).

III. RESULTS

A. Efficacy of Ivermectin (Ivertin®) against Skin Lesions in Goats

Goat of Group-B showing skin lesions treated with Ivertin® injection 1 ml /50 kg (each ml contains 10mg ivermectin) body weight subcutaneously around the lesions showed slight improvement after the first injection of treatment, which was assessed by reduction of itching, irritation, and progressive drying. After application of 2nd dose on the 7th day, there was significant improvement with a reduction of the size of the lesions. After applying the 3rd dose

on the 14th day, treated lesions were wholly healed up by the formation of smooth black scar tissue within the 28th day of the first injection (Fig. 1&2).



Fig. 1. The healing of skin lesions at 28th day of treatment with Ivertin®

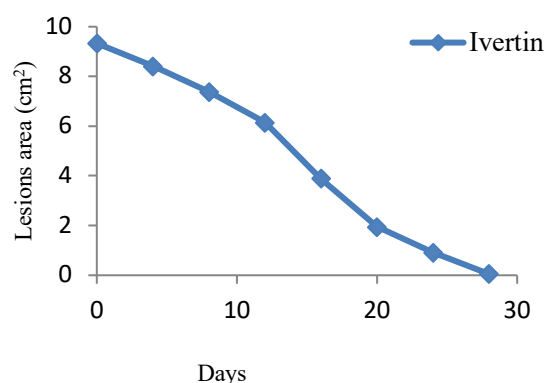


Fig. 2. Efficacy of Ivertin against skin lesions in goats.

B. Efficacy of Ivermectin (A-Mectin®) against Skin Lesions in Goats

Goat of Group-C showing skin lesions treated with A-Mectin® injection 1 ml /50 kg (each ml contains 10mg ivermectin) body weight subcutaneously around the lesions showed slight improvement after the first injection of treatment, which was assessed by reduction of itching, irritation and progressive drying. After application of 2nd dose on the 7th day, there was significant improvement with a reduction of the size of the lesions. After applying the 3rd dose on the 14th day of treatment, lesions were completely healed up by the smooth black scar tissue formation within the 28th day of first injection (Fig. 3& 4).



Fig. 3. The healing of skin lesions on the 28th day of treatment with A-Mectin®.

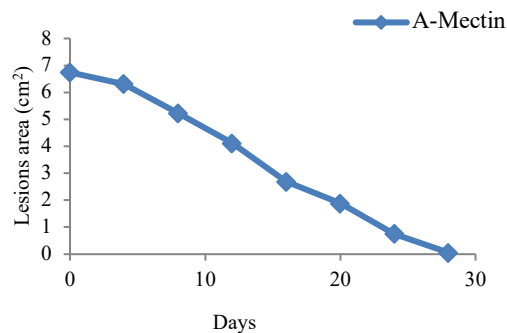


Fig. 4. Efficacy of A-Mectin against skin lesions in goats.

C. Efficacy of Ivermectin (Invet®) against Skin Lesions in Goats

Goat of Group-D showing skin lesions treated with Invet® injection 1 ml /50 kg (each ml contains 10 mg ivermectin) body weight subcutaneously around the lesions showed slight improvement after the first injection of treatment which was assessed by reduction of itching, irritation, and progressive drying. After application of the 2nd dose on the 7th day, there was significant improvement with a reduction of the size of the lesions. After applying the 3rd dose on 14th day of treatment, lesions were wholly healed up by the formation of smooth black scar tissue within 28th days of first injection (Fig. 5 & 6).

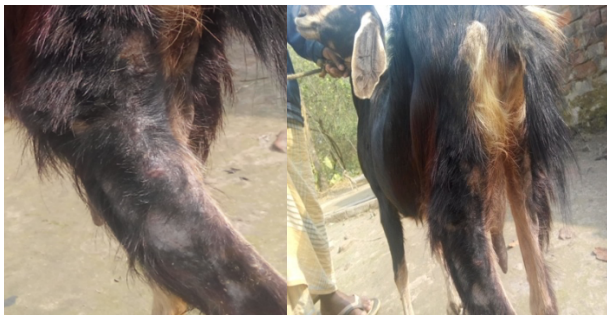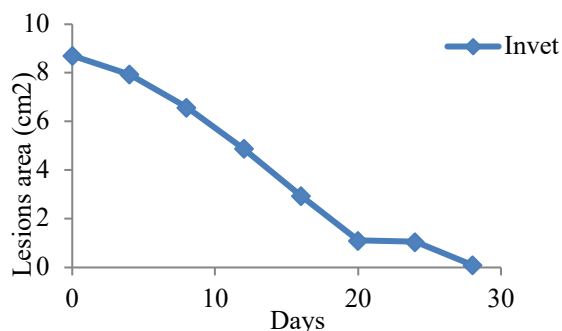
Fig. 5. Photograph of the healing of skin lesions at 28th day of treatment with Invet®.

Fig. 6. Efficacy of Invet against skin lesions in goats.

D. Comparative Efficacy of Different Commercial Preparations of Ivermectin against Skin Lesions in Goats

Ivertin® of Chemist Laboratories Ltd, A-Mectin® of ACME Laboratories Ltd and Invet® of Popular Pharmaceutical Limited was administered respectively in sub-cut route to the goats of group B, Group C, and Group D on 1st day, 2nd dose at the 7th day and last dose at the 14th day of experimental trials whereas group A was kept as control (Fig. 7). In the treatment of Ivermectin, both smaller and larger skin lesions were almost cured within 28 days at a rate

of 99.46% with Ivertin®, 99.11% with A-Mectin®, and 98.85% with Invet® respectively to the goats of group B, Group C, and Group D (Fig. 8).

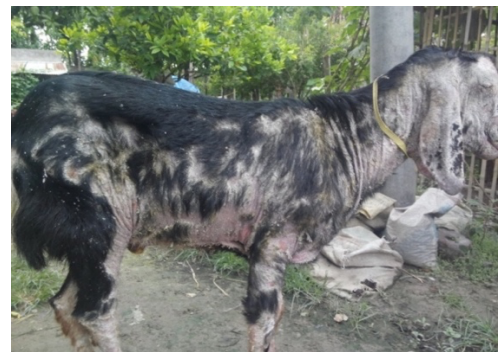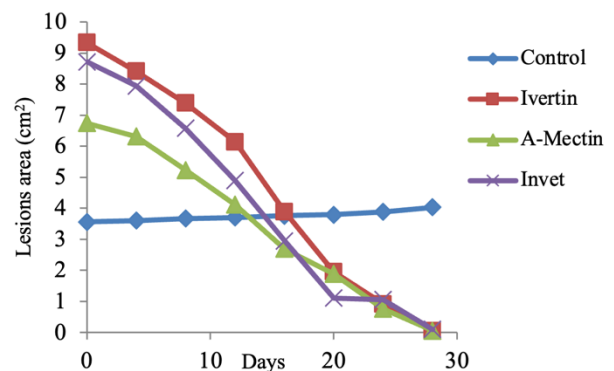
Fig. 7. Skin lesions on the 28th day of the experiment (control).

Fig. 8. Comparative efficacy of Ivertin, A-Mectin and Invet against skin lesions in goats with untreated goats.

E. Fate of Goats of Group-A (control group)

The lesions in the goats of Group A did not show any improvement during the period of the experimental trials (Fig. 9).

The above findings show that the drugs of all three leading companies that have been brought under experiment were effective against skin lesions and worked more or less similar. No adverse effects were observed during the experimental period.

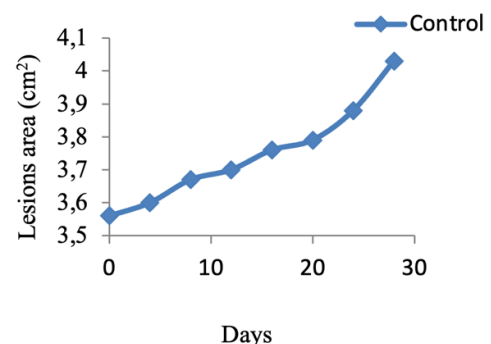


Fig. 9. Effect of untreated condition on skin lesions in goats.

Our results revealed subcutaneous application of Ivermectin was effective against skin lesions in goats with a high percentage of recovery rates. In almost every case, ivermectin proved to be highly effective and safe, and we did not notice any adverse animal reaction whatsoever. Post therapy skin lesions of both smaller and larger dimensions of the goats comprising groups B were in a state of almost cured

within 28 days at a rate of 99.46% with Ivertin® but the lesions in the goats of Group A did not show any improvement during the period of the experimental trials.

IV. DISCUSSION

Ivermectin has been on the veterinary market for almost a quarter of a century and has been approved for human use for 18 years. Its use has revolutionized the treatment of nematode and arthropod parasites in animals and has provided hope for the control or even eradication of filariasis in humans. Hence, Ivermectin has earned the title of 'wonder drug'. The chemical group of Ivermectin is Avermectin, (Macrocyclic lactone). Its mode of action is Ivermectin binds to glutamate-gated chloride channels in the parasite's nervous system, causing them to open. This drug is rapidly absorbed from the gut, less quickly from a subcutaneous site, and leaves the body feces like Ivermectin. Half-life in dogs is about 24 to 36 hours. Toxicity in collies (Australian sheepdogs) and some collie mix toxic signs (lethargy, ataxia, and coma) appear above 0.1 mg/kg. In other dogs, toxic signs are seen at doses at and above 0.8 mg/kg. (Cats probably about the same as for dogs). Subcutaneous administration of horse, pig, and cattle preparations to dogs or cats may cause local problems due to the vehicle [13]. Ivermectin a patent drug, which has been found highly effective against humpsores in Bangladesh and abroad [14], [15].

In the present study, application of Ivertin® of Chemist Laboratories Ltd, A-Mectin® of ACME Laboratories Ltd, and Invet® of Popular Pharmaceutical Limited subcutaneously @ 1 ml/50 kg (each ml contains 10mg ivermectin) body weight was found 99.46%, 99.11% and 98.85% effective in group B, C, D experimental goats respectively without any side effect. Animals with both larger and smaller lesions were cured within 28 days of treatment. After the first treatment, the percentage of healing of the lesion was not so remarkable. In subsequent treatment on the 7th and 14th days, the recovery was remarkable with scar tissue formation and growth of new hair around the scar tissue. It may be due to the solid antiparasitic action of the Ivermectin. The present finding has a close correlation with the researchers Gill and Venugopal [14], [15].

Reference [14] used 1% w/v injectable solution of Ivermectin subcutaneously once at 200µg per kg body weight in 20 cattle at Gauhati, Assam, India, and 19 cattle at Port Blair (Anclaman) India. On day 28, we found no adult worms in the lesions of treated 39 cattle. The lesions in 16 of the 20 treated cattle at Gauhati (80%) were completely healed, and the lesions in the rest four were distinctly reduced in size. The slight variation of the present findings with the finding of Gill may be due to the variation at a geographical location.

Scientist from India reported that subcutaneous injection of Ivermectin 1 ml/50 kg body weight in two doses at 28-day intervals to 15 buffaloes cured 13 (80% cattle) [15]. The slight variation of the findings of the present study with the findings of Venugopal may be due to the variation of species.

V. CONCLUSION

Ivermectin has remained an antiacaricidal first drug of choice in veterinary medicine for a couple of decades but still much to learn about this wonder drug. The precise mode of action and interactions of the drug is still unrevealed; however, present research revealed its high therapeutic effectiveness against ectoparasitic skin lesions in goats. Further research is warranted with larger experimental populations and with other livestock to substantiate our findings and divulge the mystery of this drug.

CONFLICT OF INTEREST

Authors declare that they do not have any conflict of interest.

REFERENCES

- [1] Habib MA. Study on the red Chittagong cattle- an animal genetic resource of Bangladesh. M.S. Thesis, Bangladesh Agricultural University; 2001.
- [2] Paul HL, Antunes A.P.M., Covington AD, Evans P, Philips PS. Bangladeshi Leather Industry: An Overview of Recent Sustainable Developments. *Journal- Society of Leather Technologists and Chemists*. 2013; 97(1): 25-32.
- [3] Debnath NC, Sil BK, Selim SA, Prodhan MAM, Howlader MMR. A retrospective study of calf mortality and morbidity on smallholder traditional farms in Bangladesh. *Prev. Vet. Med.* 1990; 9: 1-7.
- [4] Samad MA. Observations of clinical diseases in ruminants at the Bangladesh Agricultural University Veterinary Clinic. *Bangladesh Veterinary Journal*. 2001; 35: 93-120.
- [5] Hoque MS, Samad MA. Prevalence of clinical diseases in dairy cross-bred cows and calves in the urban areas in Dhaka. *Bangladesh Veterinary Journal*. 1996; 30: 118-129.
- [6] Steel JW. Pharmacokinetics and metabolism of avermectins in livestock. *Veterinary Parasitology*. 1993; 48: 45-47.
- [7] Campbell WC, Benz GW. Ivermectin: a review of efficacy and safety. *Journal of Veterinary Pharmacology and Therapeutics*. 1984; 7: 1-16.
- [8] McKellar QA, Benchaoui HA. Avermectins and milbemycins. *Journal of Veterinary Pharmacology and Therapeutics*. 1996; 19: 331-351.
- [9] Van Voorhis WC, Van Huijsduijnen RH, Wells TNC. Profile of William C. Campbell, Satoshi Omura, and Youyou Tu, 2015 Nobel Laureates in Physiology or Medicine. *Proc. Natl. Acad. Sci.* 2015; 112: 15773-15776.
- [10] Burg RW, Miller BM, Baker EE, Birnbaum J, Currie SA, Hartman R, et al. Avermectins, new family of potent anthelmintic agents: producing organisms and fermentation. *Antimicrob Agents Chemother.* 1979; 15(3): 361-367.
- [11] Campbell WC. An introduction to the avermectins. *N. Z. Vet. J.* 1981; 29: 174-178.
- [12] Omura S, Crump A. The life and times of Ivermectin: A success story. *Nat. Rev. Microbiol.* 2005; 2(12): 984-989.
- [13] Woodruff HB, Burg RW. The antibiotics explosion. Pharmacological Methods, Receptor and Chemotherapy (Eds: Pamham, M. J., and Bruinvels, J). *Microbiol.* 1986; 3: 338-341.
- [14] Gill BS, Singh J, Balakrish P, Hossain M. Treatment of humpsores (Stephanofilaria) of cattle with Ivermectin. *Indian Journal of Animal Science*. 1988; 58: 552-560.
- [15] Venugopal K, Rao R, Gaffar AA. Therapy of stephanofilarial ear sore in buffaloes, comparative efficacy of ivermectin and Amitas. *Indian Journal of Veterinary Medicine*. 1992; 12: 57-58.